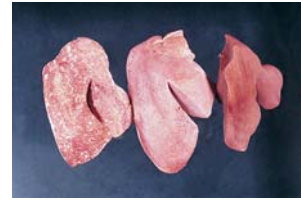
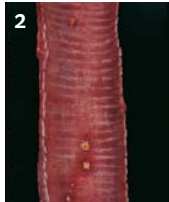


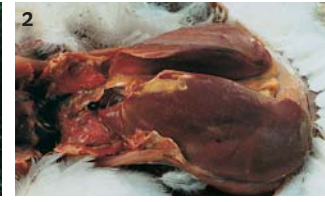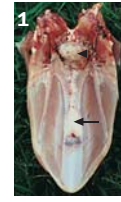**Avian Encephalomyelitis:** Avian encephalomyelitis is often called endemic tremors since birds are ataxic and have slight muscle tremors of the head. This picture shows infected birds with lack of coordination.



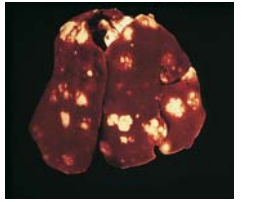
**Fowl Pox:** Picture 1 shows a pox lesion on the comb of a breeder. Picture 2 shows lesions in the trachea from the wet form of pox. Lesions can be severe enough to cause suffocation.



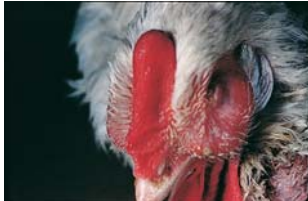**Lymphoid Leukosis:** Lymphoid leukosis is a viral disease which produces visceral tumors. Two livers from infected birds are compared to the normal liver on the right. Note the enlargement and mottling of the livers due to the tumors.



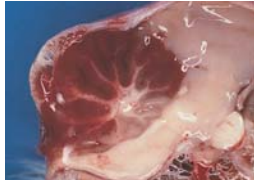**Myeloid Leukosis:** Myeloid leukosis is a complex disease caused by Avian Leukosis Virus Subgroup J. The virus can spread both vertically and horizontally. Lesions often consist of tumors of the myelocytic cell lineage in various tissues. Tumors associated with bones are commonly seen. Picture 1 shows tumors on the keel bone. Picture 2 shows a grossly enlarged liver due to tumor cell infiltration.



**Tuberculosis:** Tuberculosis produces yellow caseated nodules throughout the body. This picture shows nodules in the liver.



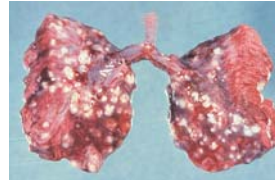
**Mycoplasmosis:** *Mycoplasma gallisepticum* affects the respiratory tract causing swelling of the infraorbital sinuses and airsacculitis. When infection occurs in combination with other respiratory pathogens, birds can develop chronic respiratory disease. *Mycoplasma synoviae* causes mild respiratory problems. It is more often associated with joint infections leading to swollen joints.



**Encephalomalacia:** Encephalomalacia can be caused by vitamin E deficiency. Chicks will show signs of incoordination. Minute hemorrhages can be found on the surface of the cerebellum.



**Infectious Coryza:** *Avibacterium paragallinarum* is the etiological agent for Infectious Coryza. The predominant feature is the involvement of the nasal passages and sinuses. Notice the severe facial edema and swelling. Sinuses and the subcutaneous space contain caseous material.



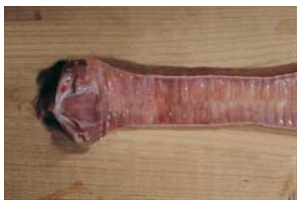**Aspergillosis:** Aspergillosis infection usually occurs in young chicks. Chicks show signs of respiratory distress. White nodules are often found throughout the lungs.



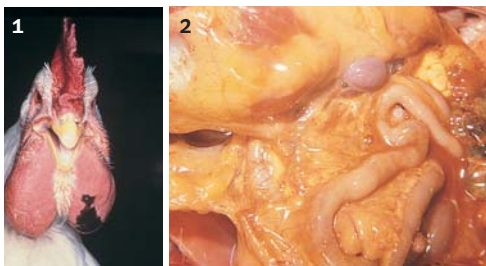**Chicken Anemia Virus:** Chicken anemia virus causes aplastic anemia and lymphoid atrophy resulting in immunosuppression. Affected birds often have severely bruised wings.



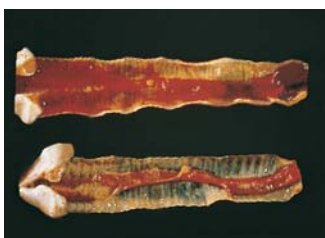**Riboflavin Deficiency:** With Riboflavin deficiency, birds are reluctant to walk. Inward curling of the toes is a typical sign of this deficiency.



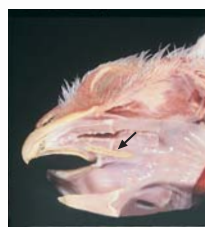**Infectious Bronchitis:** Infectious bronchitis can damage the respiratory tract, reproductive tract and the urogenital tract. Tracheitis is a common finding. Infection in mature birds causes decreased egg production and poor shell quality.



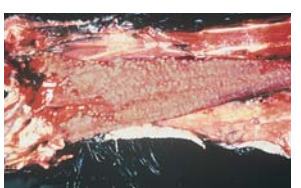
**Fowl Cholera:** Fowl Cholera is caused by *Pasteurella multocida*. Swollen wattles are a common lesion with the chronic form (Picture 1). In the acute form, mature birds may be found dead with no lesions or have a severe yolk peritonitis (Picture 2).



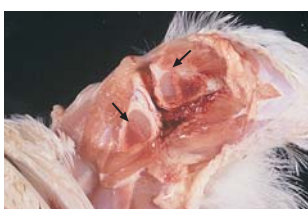**Infectious Laryngotracheitis:** Infectious laryngotracheitis produces hemorrhagic tracheitis. Infected birds may cough up blood clots. If damage is severe, the tracheal lumen will become occluded with blood.



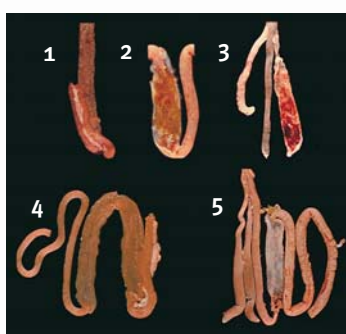**T2 Oral Lesion:** Trichothece toxins are produced when *Fusarium Sp.* of fungi grow in the feed. When ingested, these toxins produce oral lesions or burns (arrow) resulting in reduced growth rates.



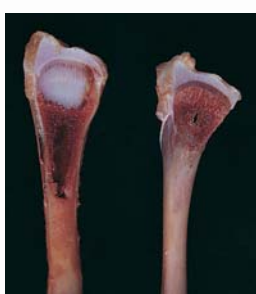
**Vitamin A Deficiency:** Vitamin A is required for proper mucous membrane development. When deficient, the mucous gland ducts become blocked and secretions accumulate forming white pustules. Notice the formation of white pustules in the esophagus.



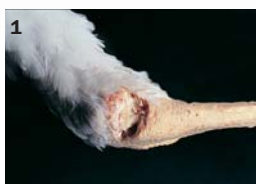**Rickets:** Rickets can be caused by calcium deficiency, phosphorous deficiency, vitamin D deficiency or an imbalance between calcium and phosphorous levels. This picture shows increased width of the growth plate from calcium deficiency (arrows). Phosphorous deficiency produces a similar problem with widening of the hypertrophy zone. Birds are reluctant to walk and bones are soft.



**Coccidiosis:** Coccidiosis is caused by protozoan parasites of the genus *Eimeria*. The above picture shows lesions from the more common species in chickens. 1 - *E. acervulina* infects the duodenum. White striations are often found with infection. 2 - *E. maxima* infects the midgut region causing enteritis. Petchial hemorrhages can be seen through the intestinal wall. 3 - *E. tenella* infects the ceca producing severe damage. Free blood can be found in the lumen. 4 - *E. necatrix* infects the midgut region. White spots (schizonts) and petechial hemorrhages are seen together. 5 - *E. brunetti* infects the lower intestinal tract producing necrosis and bloody, mucoid enteritis.



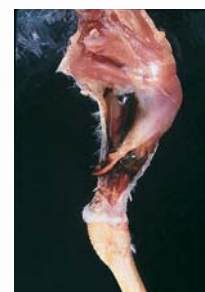
**Tibial Dyschondroplasia:** Tibial dyschondroplasia is the accumulation of irregular masses of cartilage near the growth plate. The affected bone on the left is compared to a normal bone on the right. Birds are often reluctant to walk.



**Staphylococcosis:** Infection with *Staphylococcus* spp. can cause a number of problems. Infections often result in swollen joints. Infected joints are filled with purulent exudate (Picture 1 & 2).



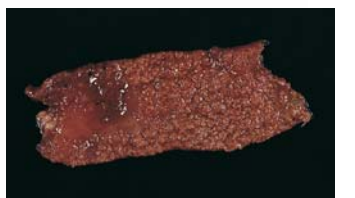**Intestinal Parasites:** Common intestinal worms include:  
A. Roundworms  
B. Tapeworms.



**Reovirus:** Reovirus causes both malabsorption syndrome and viral arthritis. When reovirus infects the intestinal tract the absorption of nutrients can be compromised. Pictured is a ruptured tendon from a bird with viral arthritis. The virus damages the tendon early in life. As the bird gains weight, the damaged tendon can rupture producing lame birds. Joints are often swollen.



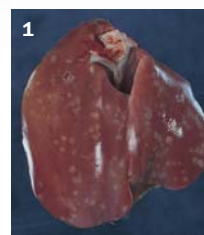
**Egg Drop Syndrome:** Egg drop syndrome affects layers and breeders. Infection during production will cause a severe decrease in egg production and poor shell quality. Eggs may have reduced pigmentation, soft shells or irregular shapes. Shell-less eggs may also be seen.



**Necrotic Enteritis:** Necrotic enteritis is caused by *Clostridium perfringens*. The disease produces severe necrosis of the intestinal tract lining. Predisposing factors include coccidiosis.



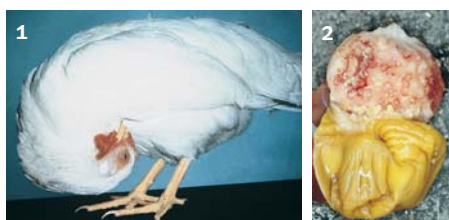**Gangrenous Dermatitis:** Gangrenous dermatitis is a subcutaneous bacterial infection usually caused by *Clostridium* and *Staphylococcus* species. This disease is often seen in birds immunocompromised. Picture 1 shows dark, moist skin on an infected bird. In Picture 2 the skin has been removed revealing subcutaneous gas production, hemorrhage and edema.



**Salmonellosis:** Fowl Typhoid is caused by *Salmonella gallinarum*. Infection with *Salmonella pullorum* produces Pullorum Disease. Both infections can produce similar lesions. Picture 1 shows white, necrotic foci throughout the liver as may be seen with Pullorum Disease. Picture 2 shows resorbed ovaries and increased spleen with necroses.



**Avian Influenza:** Signs of disease with avian influenza are varied. Birds may show decreased activity, respiratory signs, nervous system signs or diarrhea. This picture shows severe cyanosis of the unfeathered areas on the head. The bird on the right is normal compared to an infected bird on the left.



**Newcastle Disease:** Newcastle disease causes a range of problems from mild airsacculitis to neurotropic and viscerotropic lesions. Picture 1 shows a breeder with torticollis due to central nervous system damage. Picture 2 shows hemorrhages in the proventriculus glands.

The dissected bird is a seven week old broiler. Please note that some organs have been moved from their normal position for visualization.

- |               |                  |                      |                    |
|---------------|------------------|----------------------|--------------------|
| 1 Trachea     | 6 Lung           | 11 Gall Bladder      | 16 Duodenum        |
| 2 Esophagus   | 7 Heart          | 12 Ileum and Jejunum | 17 Bursa           |
| 3 Thymus      | 8 Spleen         | 13 Gizzard           | 18 Cloaca          |
| 4 Vagus Nerve | 9 Proventriculus | 14 Kidneys           | 19 Large Intestine |
| 5 Crop        | 10 Liver         | 15 Pancreas          | 20 Cecal Tonsils   |
|               |                  |                      | 21 Ceca            |